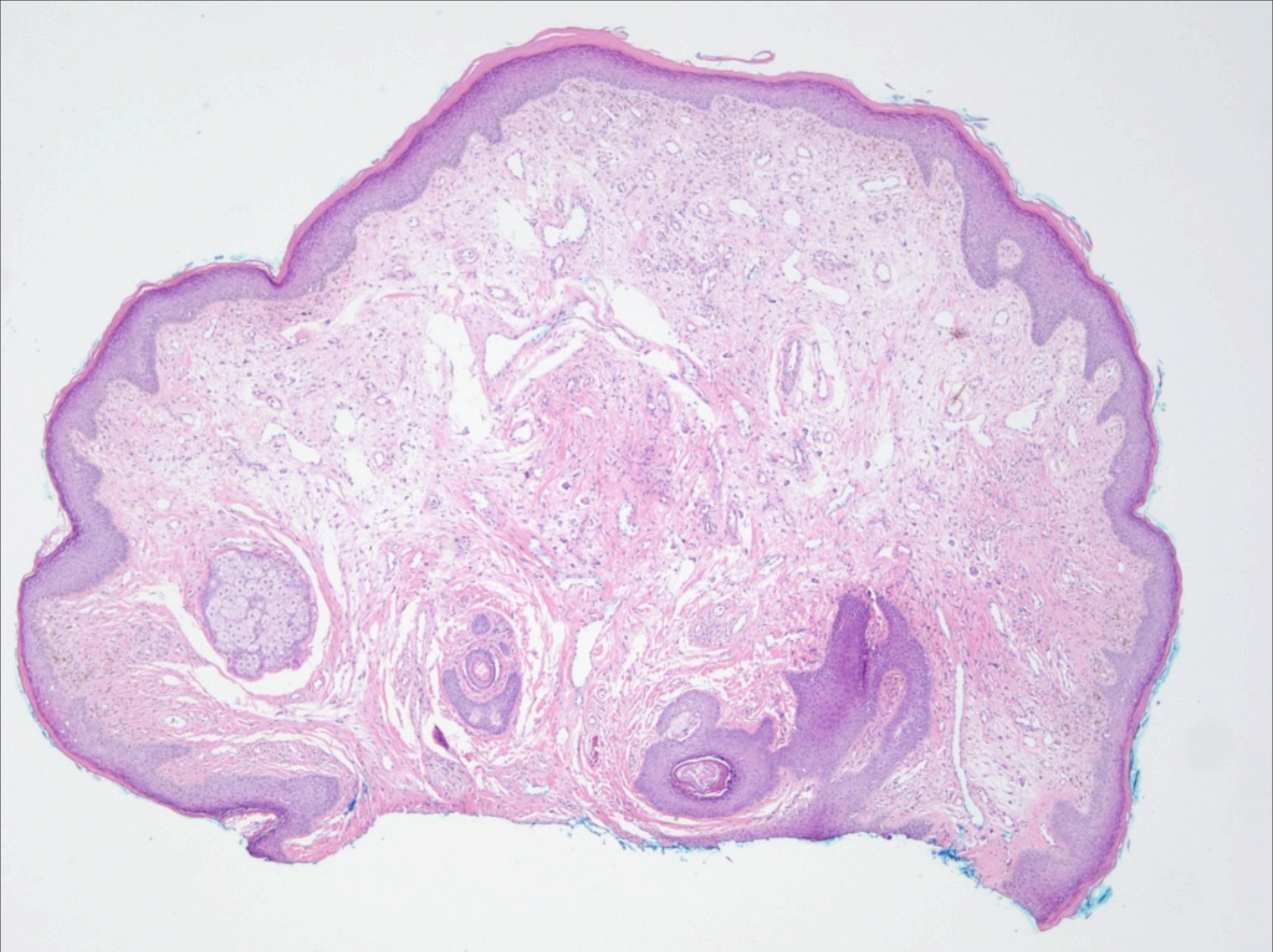
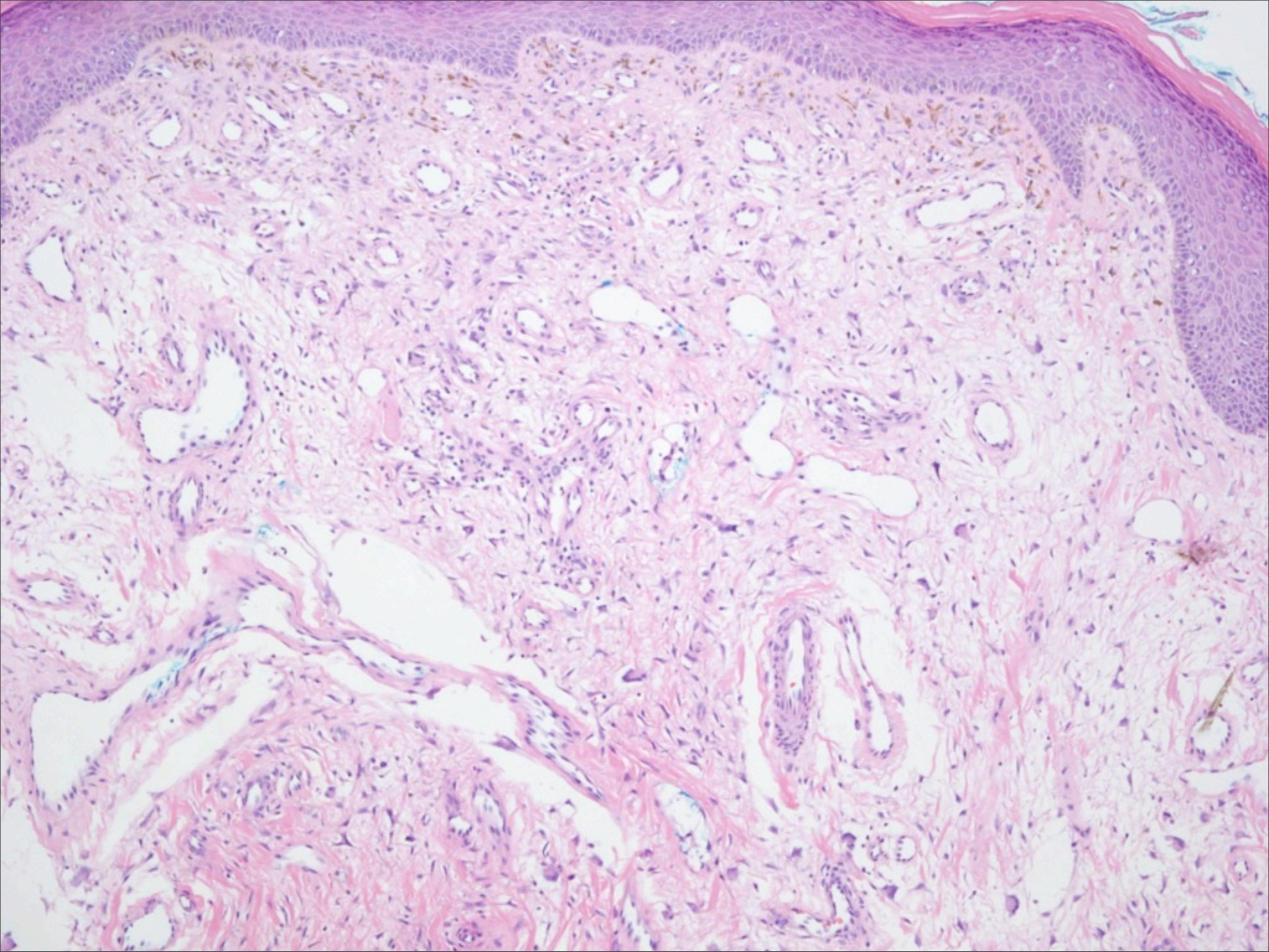
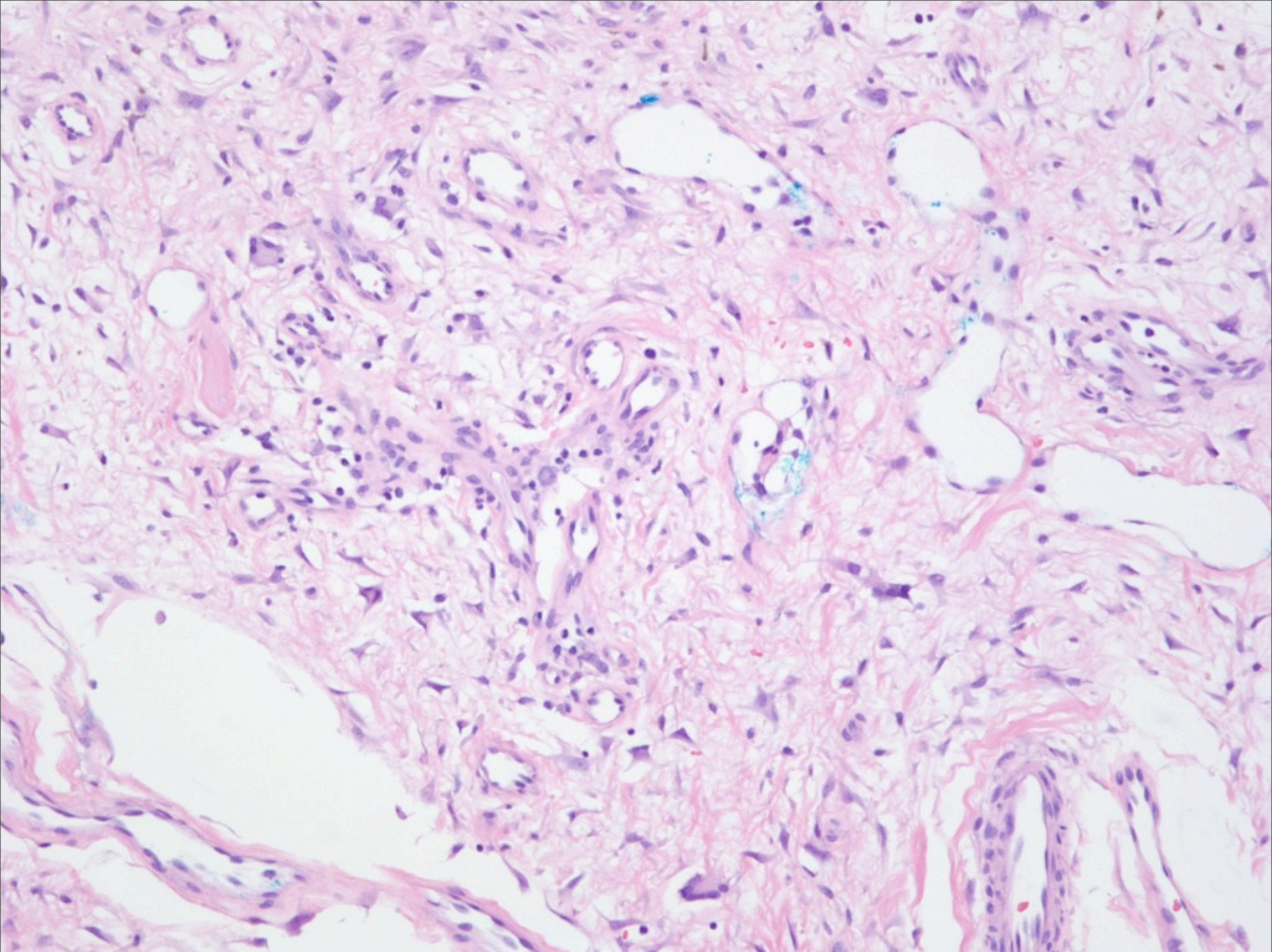

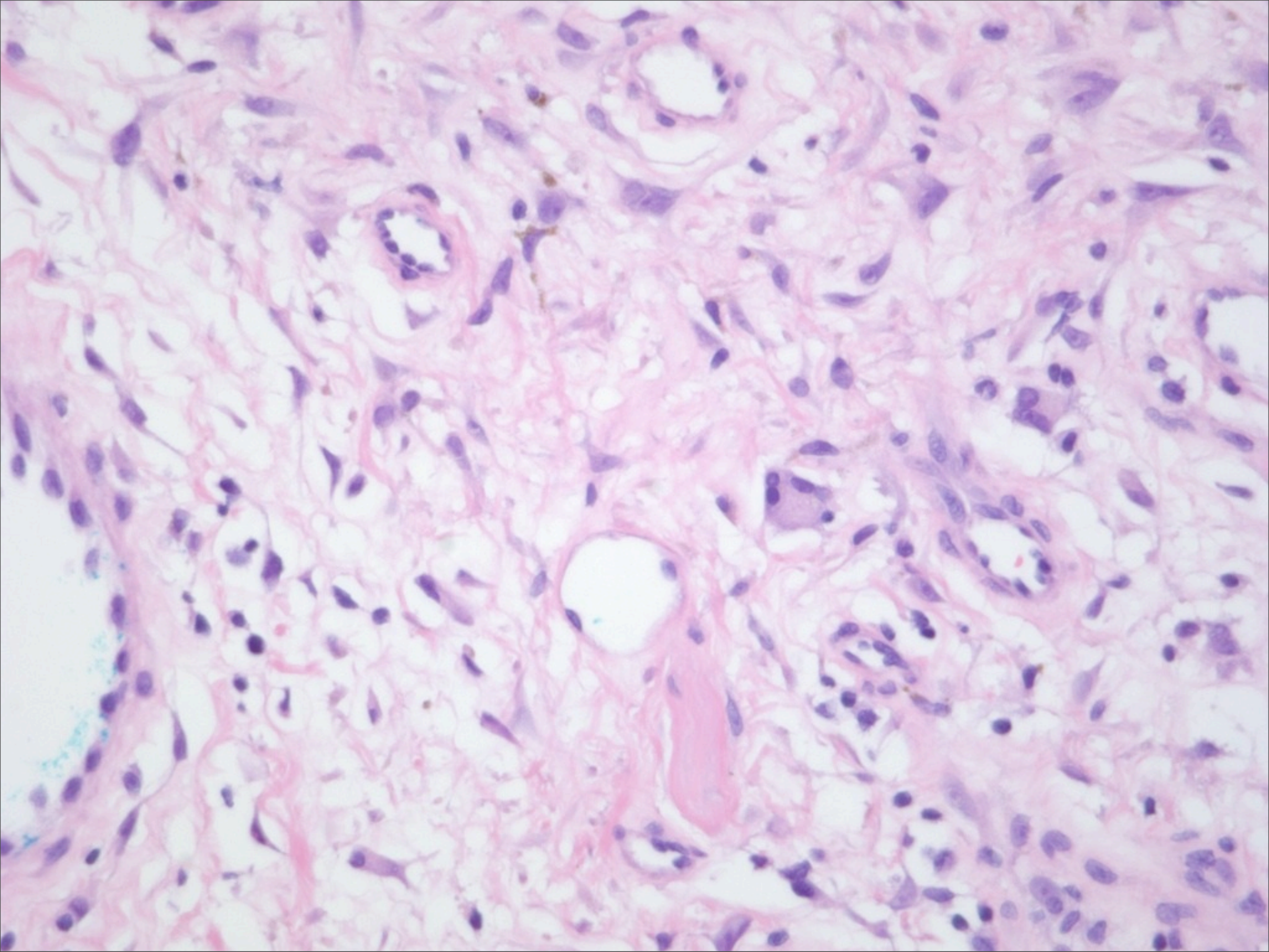# What is the best diagnosis?

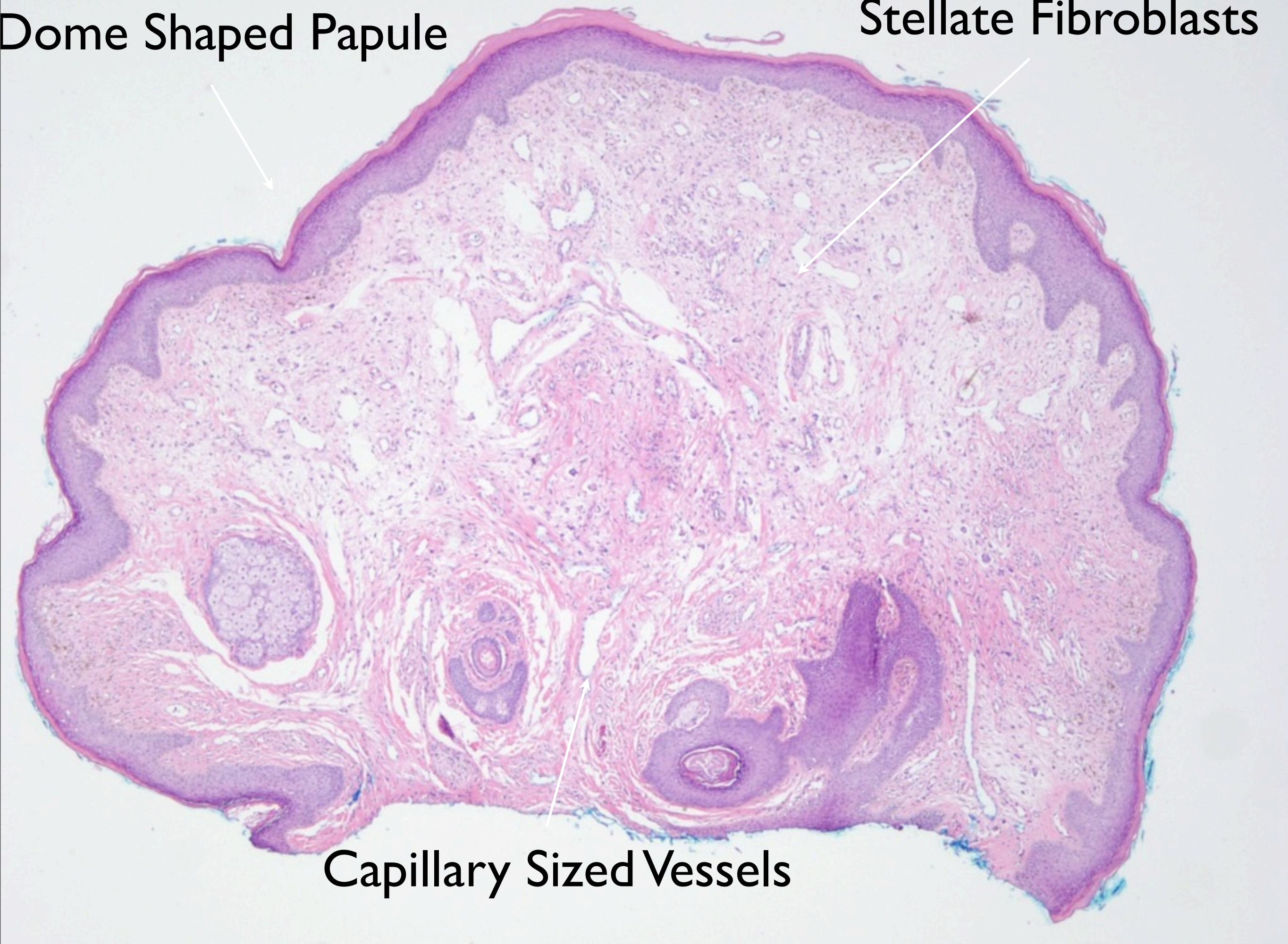
- Angiosarcoma
- Targetoid Hemosiderotic Hemangioma
- Angiolymphoid Hyperplasia with Eosinophilia
- Dabska's Tumor
- Fibrous Papule

# Fibrous Papule



**Dome Shaped Papule**

**Stellate Fibroblasts**



**Capillary Sized Vessels**